Vol. 2, No. 12

December 2017
Published by Global Dental Implant Academy

GDIA
Dental Implant
CASE REPORT

# Guided Implant Surgery: A Difficult Situation Made Easy Using DENTIS™ Simple Guide Plus®

**Cary Brown, DDS**

- Chair, GDIA Publication Committee
- General Dentist, Lake Elsinore, California
- Owner, Shift 3D Dental Works, Lake Elsinore, California

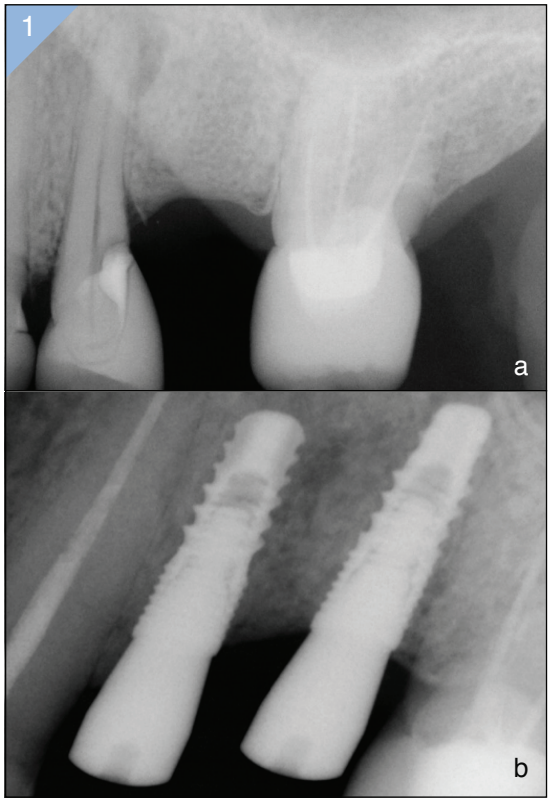


**Figure 1a,b.** a) Periapical radiograph. b) Final periapical radiograph of dental implant placement.

## Case History

One of the most challenging aspects of dental implantology is drilling and subsequent placement of the implant fixture in the correct position. It is therefore non sequitur that many clinicians began their dental implant educational journey learning to create an osteotomy free-hand, without the use of a surgical guide or template. With the incorporation of digital planning and the use of a custom, patient specific surgical guide, we can reduce the dependence for hand-eye coordination and clinical judgement when it comes to creating the ideal implant osteotomy position.[1,2,3,4] This case report outlines the process of dental implant placement using cad/cam technology and surgical instruments (DENTIS™, Simple Guide Plus®) for a fully guided dental implant procedure.

## Procedure

A member of our practice requested the replacement of two missing teeth. After a thorough examination, it was agreed to replace the teeth using dental implants as a base.

## Begin with the End in Mind

Initial planning began with a visual exam, alginate impressions for a stone cast and a cone beam computed (CBCT) scan (Sirona). The stone model is then digitized using a structured light optical scanner (Trios, 3Shape).

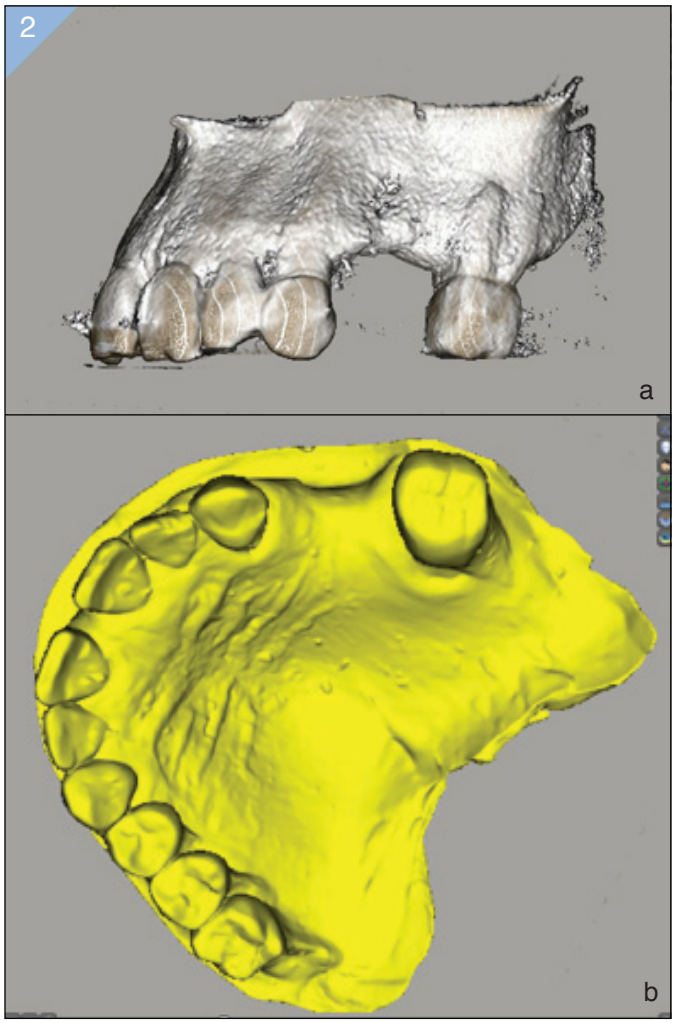


**Figure 2a,b.** a) Cone Beam Computed Tomography. Three Dimensional rendering. (Sirona XG3D) b) Structured light optical scan of pre-existing condition after removal of failed abutment tooth.

This information can be uploaded into implant planning software and the prosthetic and implant plan can be created. For the mesial-distal tooth space available, a measurement is made between the height of contour of the adjacent teeth. For the mesial distal implant space available, a measurement is made between the cervical area of the adjacent teeth.

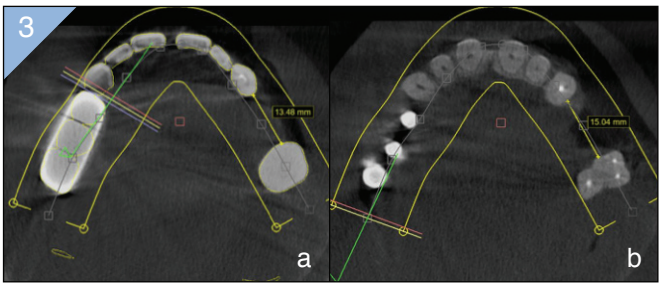


**Figure 3a,b.** a) Measurement from height of contour of adjacent teeth 13.48mm. M/D space available for crowns. b) Measurement form cervical area of adjacent teeth 15.04mm. M/D space available for dental implants.

An average premolar width is approximately 6.8mm. The available space was determined to be adequate for 2 premolar crowns.

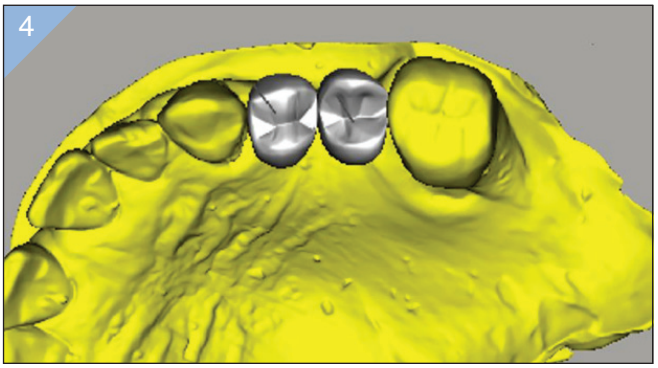


**Figure 4.** Virtual placement of premolar teeth. (BlueSkyPlan implant planning software, BlueSkyBio).

When planning the implants, some important guidelines must be adhered to. Each implant should be 1.5mm - 2.0mm away from any adjacent tooth, and each implant should be at least 3.0mm away from other implants.[5,6]

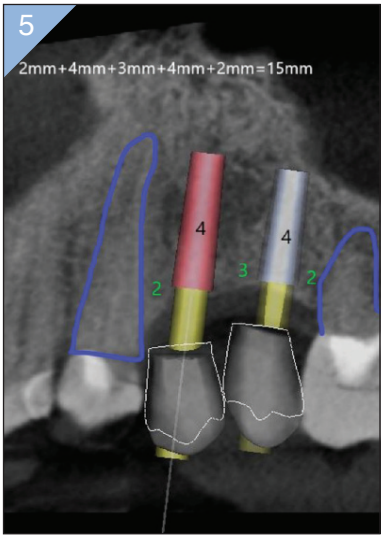


**Figure 5.** Virtual implant placement, for space evaluation. (BlueSkyPlan implant planning software, BlueSkyBio).

When taking these space requirements into account, we can see there is very little room for error in positioning and placing the dental implants.

Fortunately, with the techniques and instruments available, we can plan and execute cases like this in a very predictable fashion. It is possible to design and fabricate a surgical guide that is capable of replicating predetermined implant positions on the x,y and z axis. This guide is used to assist in the development of the osteotomy and to guide the implant carrier for final implant positioning.

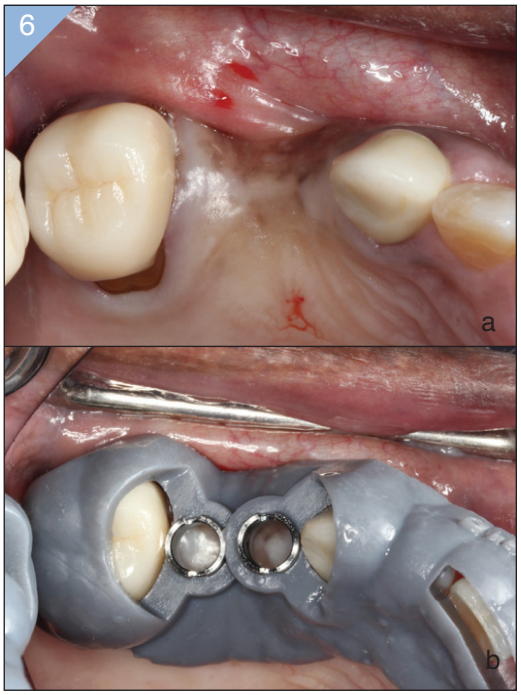


**Figure 6a,b.** a) Intra-oral photo of pre-operative condition. b) Evaluation of seating and fit of surgical guide (Simple Guide Plus®, DENTIS™).

Once the fit of the guide is verified, a specific drilling sequence is used to to complete the osteotomies according to the implant sizes.

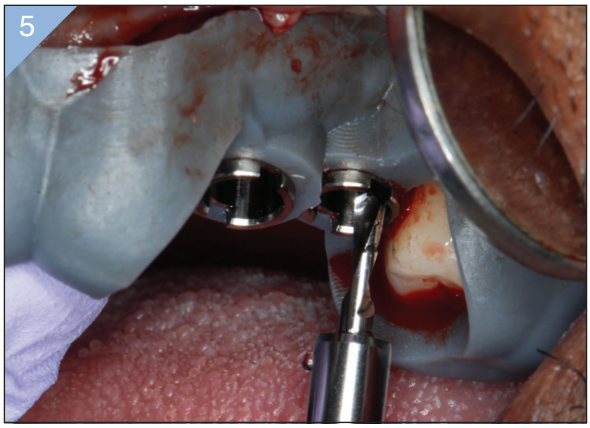


**Figure 7.** Full thickness muco-periosteal flap raised before initiating drilling sequence.


**Figure 8.** Initial pilot drill, notice close confines.

The initial pilot holes are verified using radiographic pins.

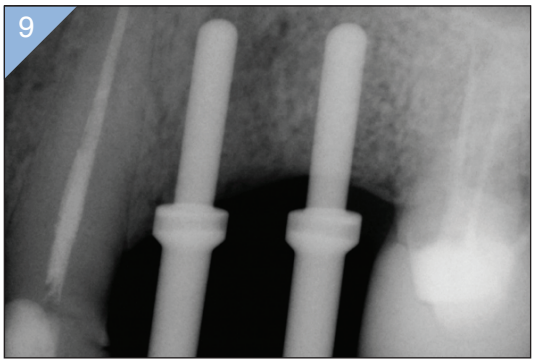


**Figure 9.** Radiograph of 2.2mm diameter pins to verify osteotomy position.

The osteotomies are completed and the implants are delivered through the guide using a manufacturer specific implant carrier (DENTIS™).

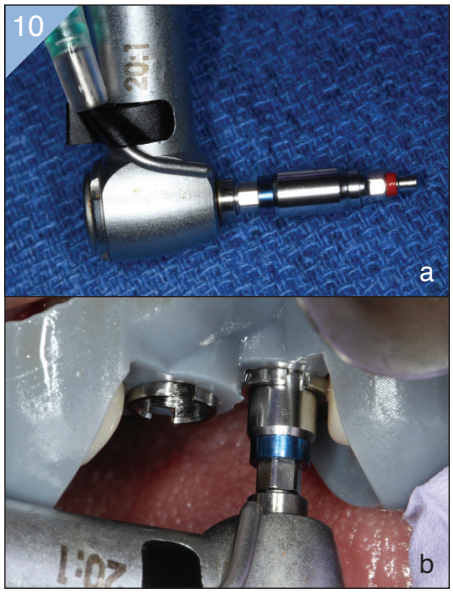


**Figure 10a,b.** a) Rotary machine implant carrier (DENTIS™ Simple Guide Plus®) included with Surgical Drilling Kit, used to deliver dental implants through the surgical guide into position. Implant carrier is not depth controlled. b) Verification of implant positions before final torquing.

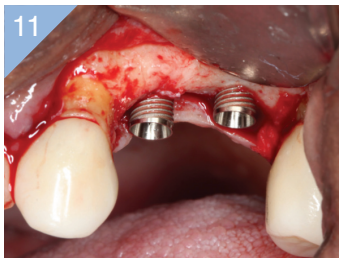


**Figure 11.** Position verified before non-guided insertion of dental implants to desired depth.

## Discussion and Conclusion

Dental implants for replacement of missing teeth are a treatment modality that is here to stay. As clinicians, we should expect our cases to last many years if not a lifetime. It is important to plan these cases carefully using all the available tools. CAD/CAM technology and the Simple Guide Plus® from DENTIS™ implant company can provide a high rate of success in difficult cases where there is literally no room for error.

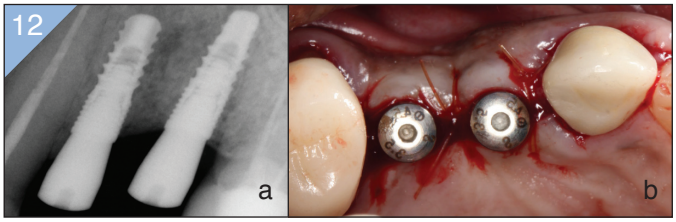


**Figure 12a,b.** a,b) Final photo of post-op clinical outcome

## References

1. Meserkhani VP, Daher T, Goodacre CJ. Comparison of the linear dimensional accuracy and detail representation in Streolithographic models of a human mandible: An in-vitro pilot study. J Impl Advanc Dent Vol. 10, No. 1; January 2018.

2. Rosenfeld A, Mandelaris G, Tardieu P, Prosthetically directed implant placement using computer software to ensure precise placement and predictable prosthetic outcome. Part 1: Diagnostics, imaging, and collaborative accountability. Int J Periodontics Restorative Dent 2006; 26:215-221. 22.

3. Rosenfeld A, Mandelaris G, Tardieu P, Prosthetically directed implant placement using computer software to ensure precise placement and predictable prosthetic outcome. Part 2: Rapid prototype medical modeling and stereolithographic drilling guide requiring bone exposure. Int J Periodontics Restorative Dent 2006; 26:347-353.

4. Sarment D, Sukovic P, Clinthorne N. Accuracy of implant placement with a stereolithographic surgical guide. Int J Oral Maxillofac Implants 2003; 18:571-577.

5. Tarnow DP, Magner AW, Fletcher P. The effect of the distance from the contact point to the crest of bone on the presence or absence of the interproximal dental papilla. J Periodontol 1992;63:995-6. 9.

6. Yu-Jen Wu, Yu-Kang Tu, Shay-Min Huang. The Influence of the Distance from the Contact Point to the Crest of Bone on the Presence of the Interproximal Dental Papilla. Chang Gung Med J 2003;26:822-8.



**Conflict of interest:**
The author declares that he has no conflict of interests relating to this article.

## Products Used

- DENTIS™, Simple Guide Plus®